

Newsletter@Star

Vol 2 Jan-Mar 2026

Greetings from Team Neuberg Star Imaging & Labs, Pune

We are pleased to present the second volume of our Newsletter featuring clinical cases and new techniques being developed and employed in day-to-day practice, to improve imaging services for you and your patients.

From this edition, we also introduce three new features in the Newsletter:

Know Your Centre highlights the key features and services available at all our five centres. This volume features our latest venture at Baner / Aundh Annexe.

Know Your Radiologists serves as an introduction to our radiologists. These are the clinical radiologists working tirelessly behind the scenes at their workstations, performing extremely complex imaging guided diagnostic / therapeutic procedures, ensuring that you and your patients receive maximum benefit from the imaging done at our scan centres.

Breaking New@STAR showcases new techniques, innovations and procedures initiated by our Radiologists and implemented in clinical practice.

We hope you enjoy reading this Newsletter as much as we have enjoyed compiling it for you.

Warm regards,
Dr. Sanjay Vaid MD
Director, Academics

Know Your Centre

Neuberg Star Imaging & Labs, Baner, was started with a singular vision — to deliver world-class diagnostic services built on patient-centric care and cutting-edge technology. Serving Baner, Aundh, and the surrounding communities, we aim to make advanced, reliable healthcare easily accessible to all. Our centre is equipped with the Widest Bore 3T MRI scanner, a 160-slice CT scan offering superior comfort, speed, and precision in diagnostics. We provide comprehensive subspecialty radiology services such as Sonography, Bone Densitometry and Digital X-Ray, along with Neuro Radiology, Paediatric Imaging, Musculoskeletal Imaging, Body and Liver Imaging, Head and Neck Radiology, and Cardiac Imaging. With state-of-the-art imaging and laboratory capabilities, Neuberg Star Imaging & Labs prioritises accuracy, safety, and patient well-being, thus earning the trust of doctors and the community alike.

NEUBERG STAR IMAGING & LABS — Where technology meets trust, and precision powers better health.

Know Your Radiologists



Dr. Nishita Pradhan

Dr. Nishita Sainath Pradhan completed her DNB Radiodiagnosis from Jehangir Hospital, Pune, where she subsequently worked as a Consultant Radiologist for four years. She chose to pursue a dedicated Fellowship in Body Imaging at Neuberg Star Imaging & Labs, where she received advanced training in cross-sectional body imaging, (especially MR fistulography, MR urethrograms, MR defecography and multiple other advanced imaging procedures). She further expanded her expertise to include image guided procedures including biopsies, drainages, thoracocentesis and paracentesis. On completing her Fellowship, Dr. Pradhan joined Neuberg Star as a Consultant, and is currently an integral part of the Body Imaging and Interventions team.



Dr. Daneshwari Kalage

Dr. Daneshwari Kalage completed her MBBS from KIMS, Hubli, Karnataka and obtained an MD in Radiodiagnosis from PGIMER, Chandigarh.

She was deeply intrigued by the power of imaging to unveil subtle clinical insights that could transform patient management. Dr. Kalage's key areas of interest include body imaging, women's imaging, and neuroimaging.

She remains committed to advancing diagnostic excellence through continuous learning and innovation.



Dr. Vaishali Nimbkar MD
Chief, Body Imaging Division

CASE 1

A 39 year-old female patient presented with history of abdominal pain and menorrhagia.

Sonography study revealed a bulky uterus with a large bilobed left ovarian hemorrhagic cystic lesion. Her CA 125 levels were within normal limits.

The MR was performed for further characterisation of the cystic lesion.

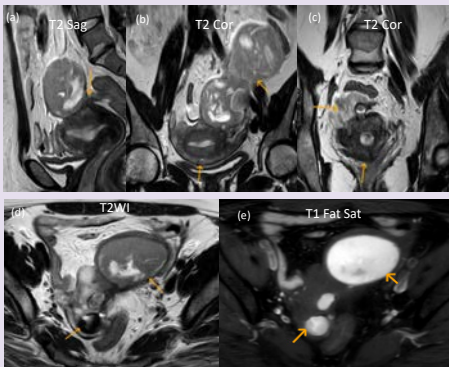


Fig 1. The MR imaging revealed an endometriotic plaque in the region of torus uterinus, with adherence of anterior wall of the rectum in this region (a). The bilateral adnexal structures were displaced medially and adherent to the uterus, representing sequelae of deep pelvic endometriosis (b & c). Bilateral ovarian endometriotic cysts were seen, appearing hyperintense on T1WI and showing T2 shading (d & e).

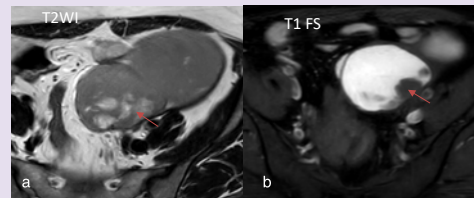


Fig 2. A large bilobed appearing left adnexal lesion is seen, appearing hyperintense on T1WI (b) with T2 shading (a), with few solid appearing components within the inferomedially located component (red arrows).

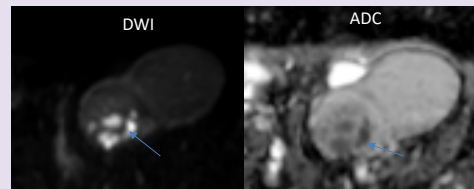


Fig 3. These solid areas show diffusion restriction (blue arrow).

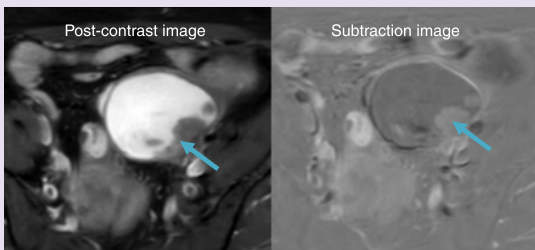
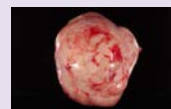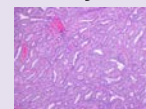


Fig 4. The solid components also show post contrast enhancement (blue arrows). The enhancement is masked on the regular images but apparent on subtraction imaging, highlighting the importance of subtraction imaging in such cases.

- The patient underwent a hysterectomy with bilateral salpingo-oophorectomy, bilateral pelvic lymph node dissection and omentectomy.



Post-operative specimen



Histopathology slide

- Post-operative histopathology showed moderately differentiated endometrioid carcinoma, FIGO grade II. No nodal involvement.
- The patient has subsequently received adjuvant chemotherapy and is doing fine.

Malignant Transformation in Endometriosis

- Malignant transformation is a rare complication of endometriosis, with reported incidence of 0.6-0.8%.
- Malignant transformation is seen as enhancing nodule within an endometriotic cyst. The enhancement is masked on regular images but apparent on subtraction imaging.
- This case highlights the importance of multiparametric MRI, especially DWI and post contrast imaging using subtraction images for detection of the enhancing nodules. This is essential for early detection and to prevent potential complications like tumor rupture during surgery.
- Endometrioid carcinoma of the ovary is the commonest histologic subtype, as was in our case, followed by clear cell adenocarcinoma.
- Some differentiating features of malignant transformation in endometriotic cyst from other ovarian carcinomas are:
 - CA 125 levels may not be elevated.
 - Ovarian carcinomas associated with endometriosis are more often seen in younger women (30–50 years of age) when compared to ovarian carcinoma in women without endometriosis, as it was in this patient.



Dr. Preeti Neve DMRD, DNB

Chief, Cardiac Imaging Division

CASE 2

- A 73 year-old gentleman presented with vague chest pain.
- Known CRF. No history of cardiac intervention.
- 2D Echo suggestive of lesion.
- A plain CT chest was done outside, revealed well-defined soft tissue density lesion along left lateral aspect of aorta.
- Cardiac MRI (plain study) was done at Neuberg Star Imaging.

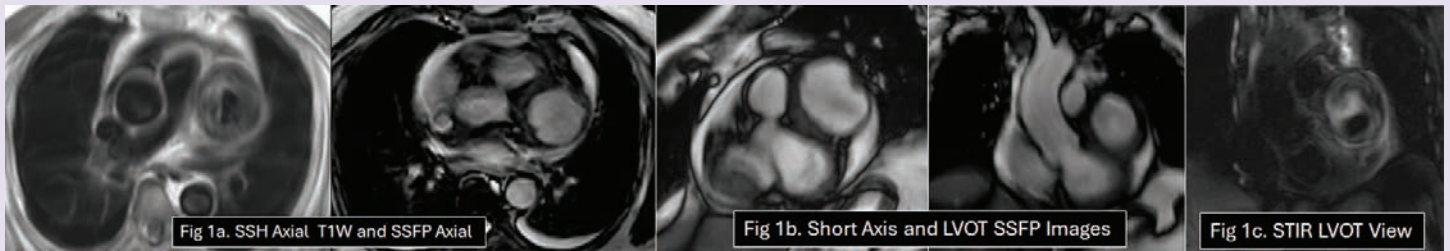


Fig 1a. SSH T1W images showing a well-defined, thick-walled heterogenous hypointense lesion along the left lateral aspect of the ascending aorta and main pulmonary artery, showing hyperintensity on SSFP axial images.

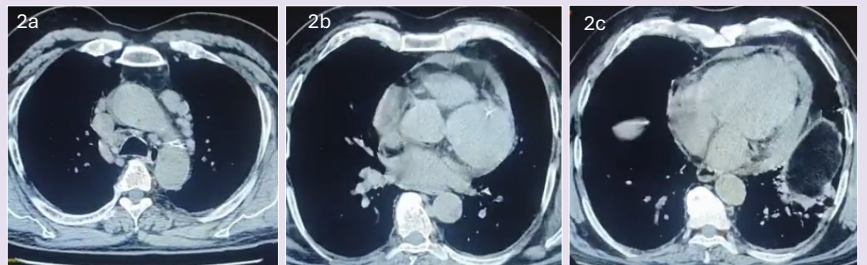
Fig 1b. SSFP images in SA and LVOT views showing thick-walled lesion with central hyperintensity. Another hypointense lesion is seen along the right posterior AV groove along distal RCA.

Fig 1c. STIR images showing heterogenous lesion.

Fig 2a. Pre-vascular mediastinal nodes.

Fig 2b. Well-defined round lesion along left lateral aspect of aortic root closely abutting LAD.

Fig 2c. Pericardial thickening.



CT images done outside were reviewed on 3D MPR, revealing lesion closely abutting the proximal LAD with calcification at entry and exit points.

Cardiac MRI done at Neuberg Star Imaging centre showed a well-defined heterogenous T1 hypointense lesion with thick walls along the left lateral aspect of the ascending aorta and main pulmonary artery showing central hyperintensity and thick irregular wall. Flow signal was seen within the lesion cavity. Another hypointense lesion was seen along the right AV groove posteriorly along the distal RCA encasing it with no demonstrable flow signal within this lesion. It indented upon the tricuspid annulus. A possibility of pseudoaneurysm along LAD was raised. The lesion along RCA was also considered to be an inflammatory response around vessel with underlying aneurysm.

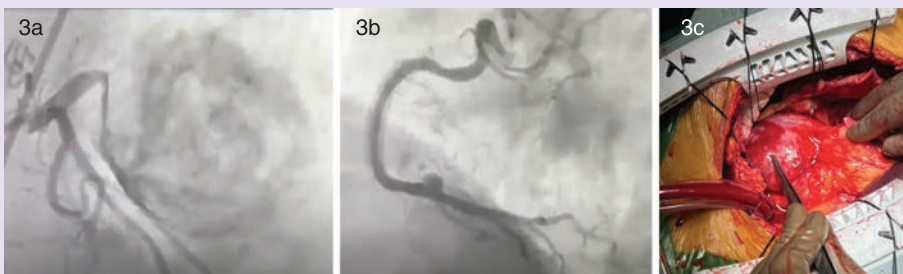


Fig 3a. CAG confirmed large aneurysm from LAD.

Fig 3b. Another smaller aneurysm from distal RCA.

Fig 3c. Intraoperative picture showing aneurysm.

CAG was performed which confirmed both findings. CT PET showed activity along the LAD lesion. A bypass surgery was performed with graft placement distal to both aneurysm sacs. Aneurysms were excised. No organism was isolated. Histopathology showed a mycotic aneurysm with thick irregular wall showing neutrophil infiltration. Patient is under treatment for the same, and is doing well post surgery.

Infected (Mycotic) Coronary Artery Aneurysm

- Infected coronary artery aneurysms represent a rare but potentially fatal complication of pre-existent atherosclerotic or non atherosclerotic coronary artery disease, percutaneous coronary artery intervention, endocarditis, or extracardiac infection.
- ICAA are typically large and characterized by a thick wall with a lobulated or saccular shape. Association with mediastinal, chest wall, or pericardial abnormalities are common.
- RCA was the most commonly affected vessel in literature reported cases. The responsible organisms include either *Staphylococcus aureus* or *Streptococcus* infection. ICAA are typically large, on average 3.4 cm in diameter, and can measure up to 9 cm. On CT imaging, features include lobulated contour or saccular shape with thick wall or mural thrombus. Associated abnormal appearance of the pericardium with either pericardial fluid, thickening, or loculation is common.



Dr. Yogeshwari Deshmukh DMRD, DNB

Chief, Neuroradiology Imaging Division

CASE 3

- A 38 yr old gentleman suffered from left sided facial pain for last 7-8 years. He was labelled as left trigeminal neuralgia.
- Clinical examination was unremarkable.

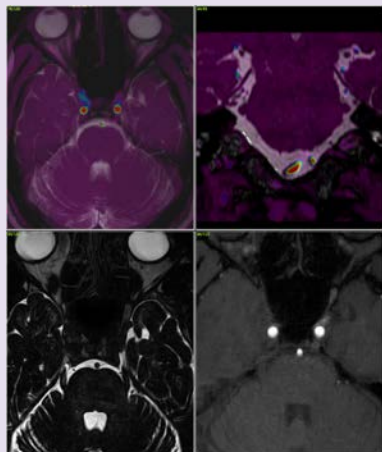


Fig 1. 3D DRIVE and superimposed DRIVE-angiography images demonstrate no evidence of neurovascular conflict. The cisternal segments of the trigeminal nerves appear normal with no aberrant vascular loop, indentation, or compression.

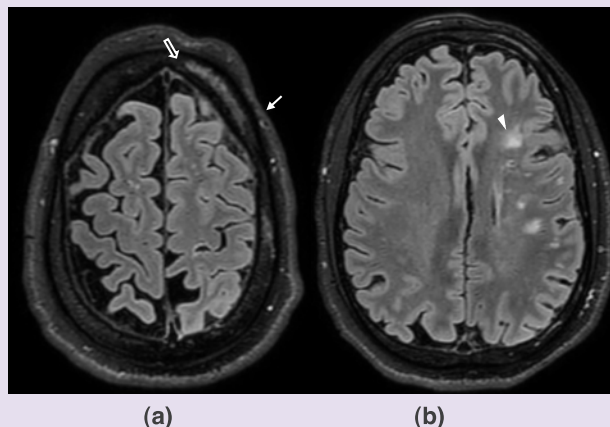


Fig 2. 3D FLAIR images show soft-tissue volume loss involving the left half of the frontal scalp (↓) with thinning of the underlying left frontal bone, which also shows marrow hyperintensities (↓). The adjacent brain parenchyma shows no atrophy; however, multiple punctate FLAIR hyperintensities are seen in the left frontal white matter.

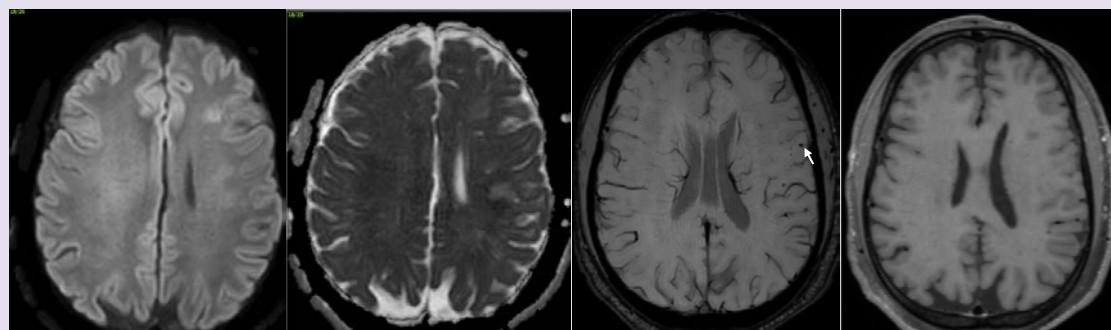


Fig 3. DWI images (a) show diffusion-bright signal without corresponding restriction on ADC maps, consistent with T2 shine-through. SWI images demonstrate punctate blooming foci in the left frontal lobe, raising the possibility of calcific foci. Post-contrast images (c) show no appreciable enhancement within the brain parenchyma.

Parry–Romberg Syndrome (PRS)

- A rare, progressive neurocutaneous disorder characterized by unilateral hemifacial atrophy involving skin, subcutaneous fat, muscle, and sometimes bone.
- PRS is not merely cosmetic but neurological involvement is known.
- Facial pain may precede visible facial asymmetry.
- Imaging can aid in diagnosis by demonstrating soft-tissue volume loss, thinning of the calvarium, and marrow signal alterations on the affected side.
- Intracranial associations may include punctate white-matter hyperintensities and SWI blooming foci suggestive of calcification or microvascular changes.
- Radiology especially MRI helps differentiate PRS from mimics such as linear scleroderma en coup de sabre, vasculitis, and demyelinating disorders.
- **Take home message:**
- In chronic unilateral facial pain and no neurovascular conflict, look beyond the nerve. Subtle unilateral scalp and calvarial changes combined with ipsilateral white matter abnormalities can uncover PRS.

Breaking New@STAR – CT / MRI Image Fusion in Head and Neck



Prof. Sanjay Vaid MD

Chief, Head Neck & ENT Imaging Division
Director, Academics

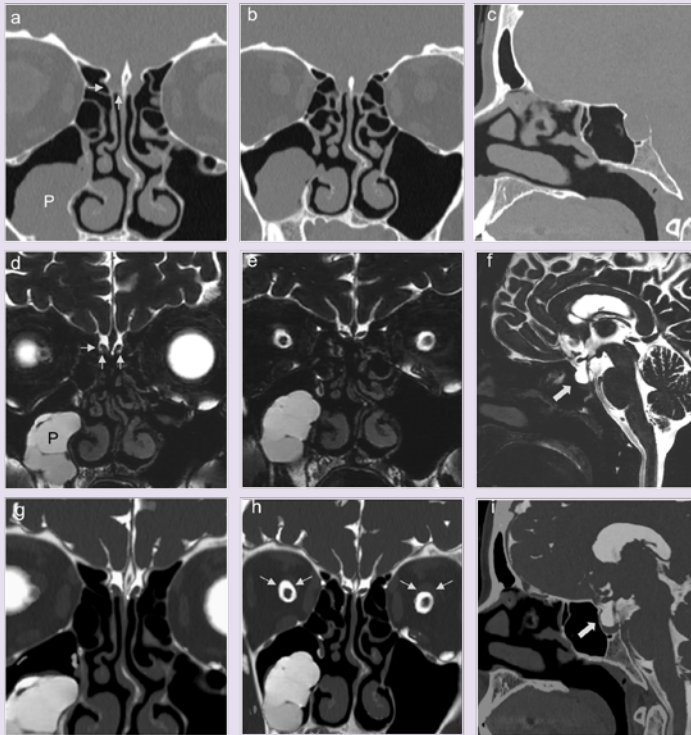


Fig 1. Imaging evaluation requested for suspected right-sided CSF rhinorrhoea.

Coronal (a, b) and right parasagittal (c) non-contrast CT images reveal intact lateral and medial lamella of the cribriform plate and fovea ethmoidalis on both sides (white arrows).

Coronal (d, e) and right parasagittal (f) non-contrast MR cisternography images show normal appearance of the olfactory fossa and olfactory bulbs on both sides (white arrows) without any evidence of T2 hyperintensity mimicking CSF extending from the intracranial compartment to the sinonasal cavity on the right side.

Fused CT and MR cisternography images (g-i) show precise registration and superimposition of the CT and MR images to confirm integrity of the bony floor of anterior cranial fossa and lack of any demonstrable active CSF leak on the right side.

Subsequently the beta-2 transferrin test (used to identify a unique protein variant called desialated transferrin found almost exclusively in CSF) was also negative further confirming the findings on the fusion CT MR cisternography. However, the patient was detected with an empty sella (block arrow) and prominent perioptic CSF spaces on MRI (oblique arrows), indicating idiopathic intracranial hypertension. Incidentally, a polyp was noted within the right maxillary sinus (P).

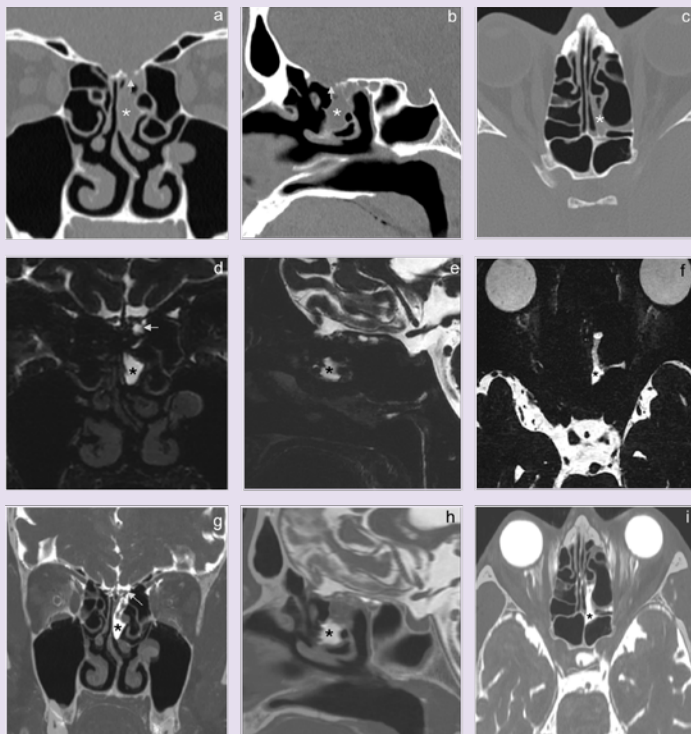


Fig 2. Imaging evaluation requested for left-sided CSF rhinorrhoea.

Coronal (a), left parasagittal (b) and axial (c) non-contrast CT images reveal focal defects in the floor of the left olfactory fossa and fovea ethmoidalis on the left side (white arrows). Soft tissue density lesions are seen within the left ethmoidal air cells below the above-mentioned defects (white asterisk).

Coronal (d) left parasagittal (e) and axial (f) non-contrast MR cisternography images show focal T2 hyperintensity (white arrow) located below the bony defects in the left olfactory fossa, mimicking CSF intensity and further extending into the left sinonasal cavity along the medial aspect of the attachment of left middle turbinate (black asterisk). This hyperintensity showed change in position with change in patient decubitus, indicating freely moving CSF.

Fused CT and MR cisternography images (g-i) show presence of the bony defect (white arrow) in the left olfactory fossa together with the site and extent of the left sided active CSF leak (black asterisk) experienced by the patient in the form of watery, left-sided nasal discharge.

Fig 3. Imaging evaluation requested for right-sided hearing loss and purulent discharge

Fig 3A. Coronal images subset

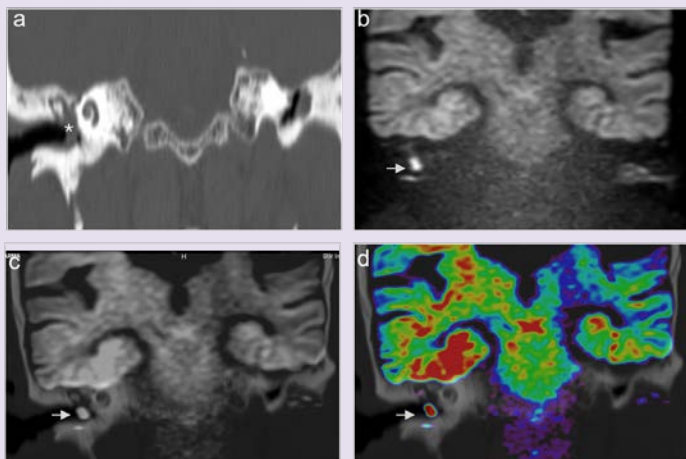
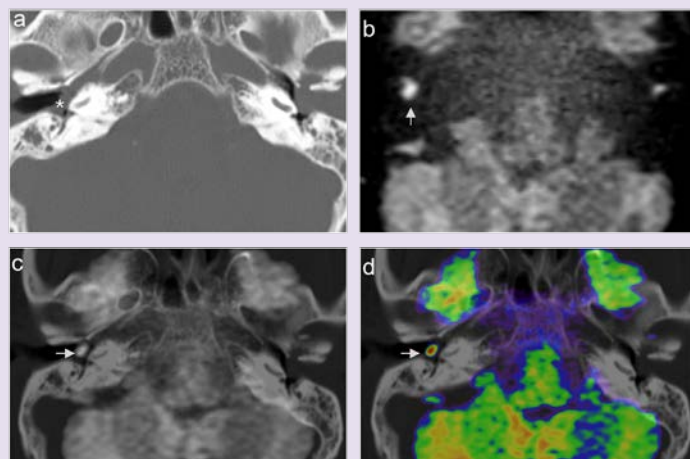


Fig 3B. Axial images subset



Coronal and axial non-contrast CT images (a) show soft tissue density lesion (white asterisk) opacifying the right middle ear cavity involving epitympanum, mesotympanum, and hypotympanum with blunting of right scutum and retracted right tympanic membrane. Turbo spin echo into (TSE) non-EPI single shot diffusion weighted (DW) coronal and axial images (b) show a small focus of restricted diffusion appearing hyperintense (white arrows) within the above-mentioned soft tissue, exhibiting low signal and low values on corresponding apparent diffusion coefficient (ADC) images.

Fused CT and MR images (c and d: colour coded) show the anatomical location of the small focus of cholesteatoma surrounded by granulation tissue within the diffuse soft tissue density lesion appreciated on CT in the right middle ear cavity. These images help in intraoperative anatomical localisation of the pathology.

Key Points

CT and MR image fusion is a revolutionary technique that uses specialised software to precisely align two sets of images from two different imaging modalities (i. e. CT and MRI images of the patient which have been previously acquired independently) to create a hybrid image that allows for a more comprehensive display of anatomy and pathology by combining information from both modalities. This technique also overcomes the limitations of each individual modality when used as a single imaging tool.

CT / MR image fusion for CSF leaks

Fusing CT images which provide excellent details of skull base defects with MR images that are uniquely sensitive to detect CSF, allows for accurate localisation of the site of CSF leak, thereby facilitating the appropriate surgical management and improving postoperative outcomes. Combining non-contrast CT with MR images also obviates the need for an invasive procedure like CT cisternography with its inherent complications and side effects for the patient.

CT / MR image fusion for detection and location of cholesteatomas

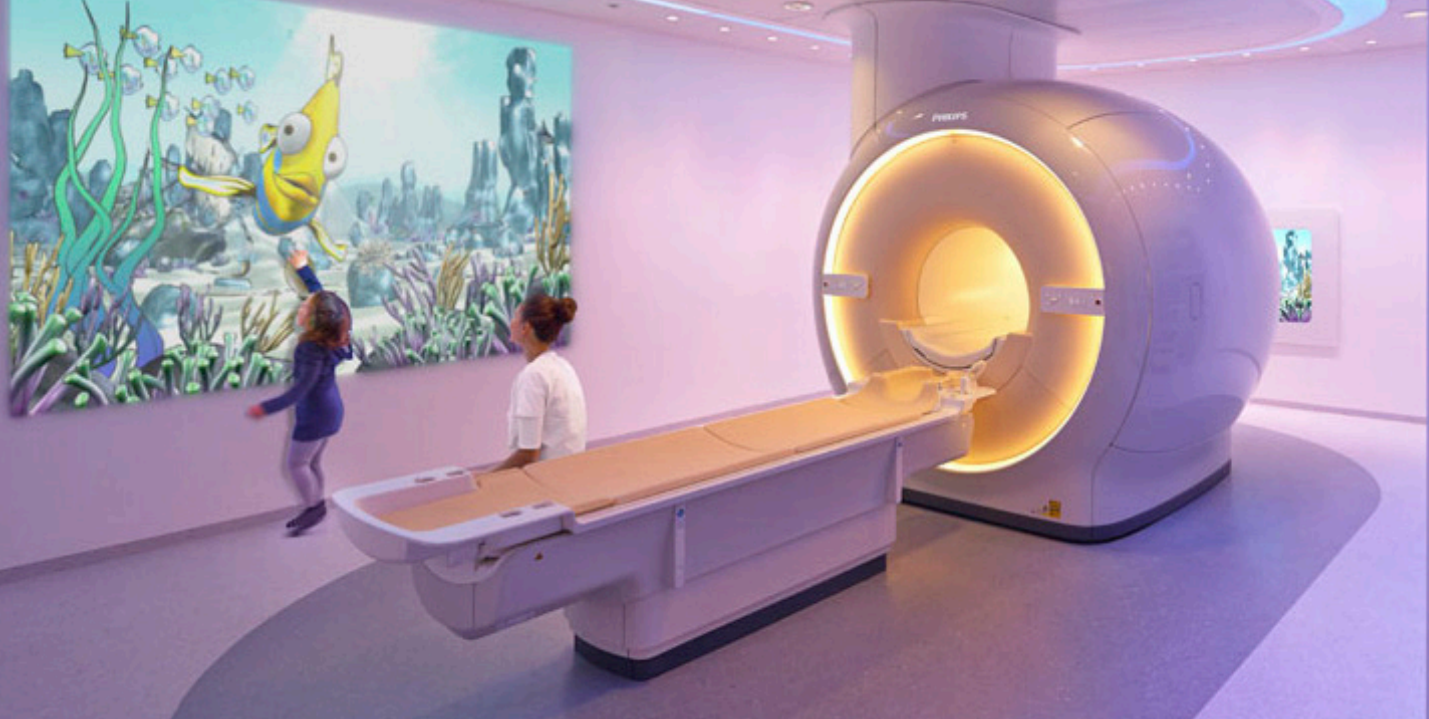CT images of the temporal bone provide exquisite details of the anatomy, extent of the disease and bony/ossicular involvement. However, CT alone cannot distinguish cholesteatoma from surrounding inflammatory/granulation/scar tissue. Turbo spin echo (TSE) non-EPI single shot diffusion weighted images (DWI) are highly sensitive to detect presence of cholesteatoma within surrounding non-cholesteatomatous tissue. Fusion of CT with DWI greatly improves localisation of the cholesteatoma, helps in assessing the full extent of the disease and enables appropriate surgical planning.

CT / MR image fusion for head and neck cancers

Fusion of CT and MR images in head and neck oncology enables better tumour boundary visualisation and identifies critical neurovascular structures near the tumour. It is also used in preoperative navigation and radiation therapy planning to ensure maximum possible concentration on the tumour while sparing the adjacent healthy tissues.

References

- 1 Mostafa BE, Khafagi A. Combined HRCT and MRI in the detection of CSF rhinorrhea. Skull Base. 2004 Aug;14(3):157-62.
- 2 Maccarrone F, Cantaffa C, Genovese M, Tassi S, Negri M. Fusion computed tomography-magnetic resonance imaging scans for pre-operative staging of congenital middle-ear cholesteatoma. J Laryngol Otol. 2024 May;138(5):507-511.



The Team at Neuberg Star Imaging & Labs

Ashish Atre • Anupama Patil • Aparna Atre • Sanjay Vaid

Joban Babhulkar • Sonali Deshmukh • Vaishali Nimbkar • Preeti Neve

Yogeshwari Deshmukh • Unmesh Bhosale • Amit Zope • Aniket Jadhav

Akshata Phade • Swati Shah • Sukhada Kulkarni • Bhagyashri Parmar

Nishita Pradhan • Daneshwari Kalage

Manali Khedkar • Prashant Kokate

India's First 3T Digital MRI with Inbore Experience

ALL DIAGNOSTIC FACILITIES UNDER ONE ROOF

3T MRI • Cardiac CT Scan • Digital Mammography with Tomosynthesis • USG & Doppler • BMD • Digital X-Ray • Scanogram • Genomics • Pathology Lab

Deccan: Joshi Hospital Campus
Opp. Kamla Nehru Park, Erandawane
Pune - 411004

Bund Garden: Connaught Place
Ground Floor, Bund Garden Road
Pune - 411001

Wakad: Solitaire Business Hub
Wakad, Pimpri-Chinchwad - 411057

Baner: 1, Deron Heights Opp.
Hotel Mahabaleshwar
Baner Road, Pune - 411045

Akluj: Shamrao Patil Medical Complex
Akluj - 413101

For Enquiries and Appointments (All Centres) Tel: 9713 611 611

Email: info@starimagingindia.in • **Website:** www.starimagingindia.com

Neuberg★STAR
IMAGING & LABS